

al. (16). Their study was designed to examine biocompatibility of the device but not its function. The results in six patients (three received the chip in 2000, and another three in 2001) have not been released as yet.

The Future

It is indeed feasible to elicit action potentials in the visual cortex using electrical impulses generated by subretinal or epiretinal devices, but a number of obstacles remain to be overcome. We need to know whether the encoding of orientation and movement perception as well as feature localization is maintained at the level of the visual cortex. How can the long-term stability of these implants, whose surfaces do deteriorate after long-term implantation, be achieved? Will retinal neurons tolerate long-term electrical stimulation without themselves being altered morphologically or functionally? What type of image can be perceived by blind patients through an epiretinal implant or the light-sensitive microphotodiodes of a subretinal implant?

The patient group best suited to test such questions by implantation of retinal prostheses may be patients with hereditary retinal degenerative diseases who are stricken with blindness yet still have intact middle and inner retinal layers. In addition, a second group of patients with certain forms of macular degeneration, including the age-related type, could benefit from retinal prostheses even at advanced stages of disease. We need to instigate long-term clinical trials to ensure that the peripheral vision still present in patients with macular degeneration is not endangered by surgical procedures and the effects of the retinal implants themselves.

In 1993, there were only two papers on retinal implants among the thousands presented at the annual meeting of the Association for Research in Vision and Ophthalmology

(ARVO). Encouragingly, 1999 saw the number of presentations rise to 33, and the numbers continue to increase. Successful testing of each major step in retinal implant development—production of implant prototypes, surgical procedures, long-term stability and biocompatibility of implant material, electrical testing in vitro as well as in animal models, recording electrical activity in animal brains—is providing essential data about the resolution required for blind patients to regain mobility in a world that very much depends on visual information. A number of international groups (44) are tackling the remaining problems associated with epiretinal and subretinal implants, and we await the outcome of clinical trials to determine the value of refined nanotechnology for treating blinding eye diseases.

References and Notes

1. H.G. Krumpalzy, V. Klaus, *Ophthalmologica* **210**, 1 (1996).
2. J. P. Rauschecker, R. V. Shannon, *Science* **295**, 1025 (2002).
3. G. E. Tassiker, U.S. patent 2,760,483 (1956).
4. G. S. Brindley, W. S. Lewin, *J. Physiol.* **196**, 479 (1968).
5. W. H. Dobelle, W. G. Mladejowski, *J. Physiol.* **243**, 553 (1974).
6. W. H. Dobelle, *ASAIO J.* **46**, 3 (2000).
7. E. M. Schmidt et al., *Brain* **119**, 507 (1996).
8. R. A. Normann, E. M. Maynard, K. S. Guillory, D. J. Warren, *IEEE Spectrum* **33**, 54 (1996).
9. R. A. Normann et al., *Vision Res.* **41**, 1261 (2001).
10. C. Veraart et al., *Brain Res.* **813**, 181 (1998).
11. A. Y. Chow, *Invest Ophthalmol. Vis. Sci.* **34** (suppl.), 835 (1993).
12. ———, V. Y. Chow, *Neurosci. Lett.* **225**, 13 (1997).
13. A. Y. Chow et al., *Invest. Ophthalmol. Vis. Sci.* **39**, 5565 (1998).
14. A. Y. Chow et al., *IEEE Trans. Neural Syst. Rehabil. Eng.* **9**, 86 (2001).
15. N. S. Peachey, A. Y. Chow, *J. Rehabil. Res. Dev.* **36**, 371 (1999).
16. G. Peyman et al., *Ophthalmic Surg Lasers* **29**, 234 (1998).
17. M. T. Pardue et al., *Exp. Eye Res.* **73**, 333 (2001).
18. E. Zrenner et al., *Ophthalmic Res.* **29**, 269 (1997).
19. E. Zrenner et al., *Vision Res.* **39**, 2555 (1999).

20. E. Zrenner et al., *Ophthalmologie* **98**, 357 (2001).
21. F. E. Gekeler et al., *Invest. Ophthalmol. Vis. Sci.* **42**, S815 (2001).
22. A. Stett et al., *Vision Res.* **40**, 1785 (2000).
23. A. Stett, T. Hermann, *Invest. Ophthalmol. Vis. Sci.* **41**, S859 (2000).
24. A. Stett et al., *Invest. Ophthalmol. Vis. Sci.* **40**, S734 (1999).
25. E. Guenther, B. Troeger, B. Schlosshauer, E. Zrenner, *Vis. Res.* **39**, 3988 (1999).
26. H. G. Sachs et al., *Invest. Ophthalmol. Vis. Sci.* **40**, S734 (1999).
27. K. Kobuch et al., *Invest. Ophthalmol. Vis. Sci.* **39**, S903 (1998).
28. K. Kohler, J. A. Hartmann, D. Werts, E. Zrenner, *Ophthalmologie* **98**, 364 (2001).
29. H. Schwahn et al., *Graefe's Arch. Clin. Exp. Ophthalmol.* **239**, 961 (2001).
30. R. Eckhorn et al., *Ophthalmologie* **98**, 4, 369 (2001).
31. U. Eysel, in preparation.
32. R. Eckmiller, *Ophthalmic Res.* **29**, 281 (1997).
33. ———, R. Hünemann, M. Becker, *Invest. Ophthalmol. Vis. Sci.* **39**, S990 (1998).
34. P. Walter et al., *Retina* **19**, 546 (1999).
35. M. S. Humayun et al., *Invest. Ophthalmol. Vis. Sci.* **40**, 143 (1999).
36. M. S. Humayun et al., *Arch. Ophthalmol.* **114**, 40 (1996).
37. M. S. Humayun, E. J. de Juan, J. D. Weiland, R. Greenberg, *IEEE Int. Solid-State Circuits TP* **12.7** (1999).
38. M. S. Humayun et al., *Vision Res.* **39**, 2569 (1999).
39. A. Santos et al., *Arch. Ophthalmol.* **115**, 511 (1997).
40. J. F. Rizzo, J. L. Wyatt, *Neuroscientist* **3**, 251 (1997).
41. J. F. Rizzo, J. Loewenstein, J. L. Wyatt, *Retinal Degenerative Diseases and Experimental Therapy*, J. G. Hollyfield et al., Eds. (Kluwer, Dordrecht, Netherlands, 1999), pp. 463–469.
42. J. F. Rizzo et al., *Invest. Ophthalmol. Vis. Sci.* **40**, S783 (1999).
43. A. E. Grumet, J. L. Wyatt Jr, J. F. Rizzo III, *J. Neurosci. Methods* **101**, 31 (2000).
44. J. F. Rizzo et al., *Ophthalmology* **108**, 13 (2001).
45. J. F. Rizzo, J. Wyatt, personal communication.
46. A. Y. Chow, personal communication.
47. We thank all of our colleagues including A. Stett, H. Haemmerle, H. Schwahn, and F. Gekeler for lively discussions. The subretinal group of the consortium is supported by the German Federal Ministry of Education and Research (BMBF) grant 01 IN 50 2A-D and 01KP0008-0012, the Pro-Retina e.V. Germany, the "Fortüne"—Program of Tübingen Medical Faculty, and the E. and K. Hochbaum Foundation.

VIEWPOINT

Sending Sound to the Brain

J. P. Rauschecker¹ and R. V. Shannon²

The cochlear implant, a microelectrode array that directly stimulates the auditory nerve, has greatly benefited many individuals with profound deafness. Deaf patients without an intact auditory nerve may be helped by the next generation of auditory prostheses: surface or penetrating auditory brainstem implants that bypass the auditory nerve and directly stimulate auditory processing centers in the brainstem.

Partial or total hearing loss has many different causes. Defects in either the outer ear or middle ear (composed of the tympanic membrane, ear drum, and auditory ossicles) result in a conductive hearing loss that can usually be remedied by insertion of a hearing aid, which amplifies sound vibrations. Profound deafness, on the other hand, is caused

by loss of the sensory hair cells in the fluid-filled, snail-shaped inner ear, or cochlea, that transduce sound waves into electrical impulses, which are then transmitted to the brain (Fig. 1). Profoundly deaf individuals who still have an intact auditory nerve have profited from the dramatic advances made over the past 30 years in the field of cochlear implants

(CIs) (1, 2). The CI is a microelectrode array implanted in the cochlea that directly stimulates the auditory nerve. With more than 40,000 patients worldwide, the success of these devices is nothing short of miraculous: Most adults are able to converse on the phone, and most children are able to be edu-

CONTINUED ON PAGE 1027

¹Department of Physiology and Biophysics, Georgetown University Medical Center, Washington, DC 20007, USA. ²Department of Auditory Implants and Perception, House Ear Institute, Los Angeles, CA 90057, USA.

CONTINUED FROM PAGE 1025

cated in mainstream classrooms. For some profoundly deaf individuals, however, even electrical stimulation of the inner ear with a CI is impossible owing to an absence or destruction of the auditory nerve. Instead, an auditory prosthesis consisting of a microelectrode array that directly stimulates one of the auditory processing centers of the brainstem, bypassing the cochlea and auditory nerve, might restore hearing to these patients. Such auditory brainstem implants (ABIs) have been under development since the late 1970s, pioneered by physicians and researchers at the House Ear Institute in Los Angeles (3), but have had only limited success. The next step in ABI evolution is already under way: Whereas conventional ABIs stimulate the surface of the ventral cochlear nucleus in the brainstem, the microelectrode array in the new generation of ABIs penetrates into the depths of the ventral cochlear nucleus, directly stimulating its neurons (nerve cells) (Fig. 2). This new approach has become feasible owing to the high-tech development of materials and electronics by researchers in the field of neural prosthetics (including CIs), as well as successful stereotactic studies carried out with permanent depth electrodes in cats, an animal with an auditory system similar to our own (4).

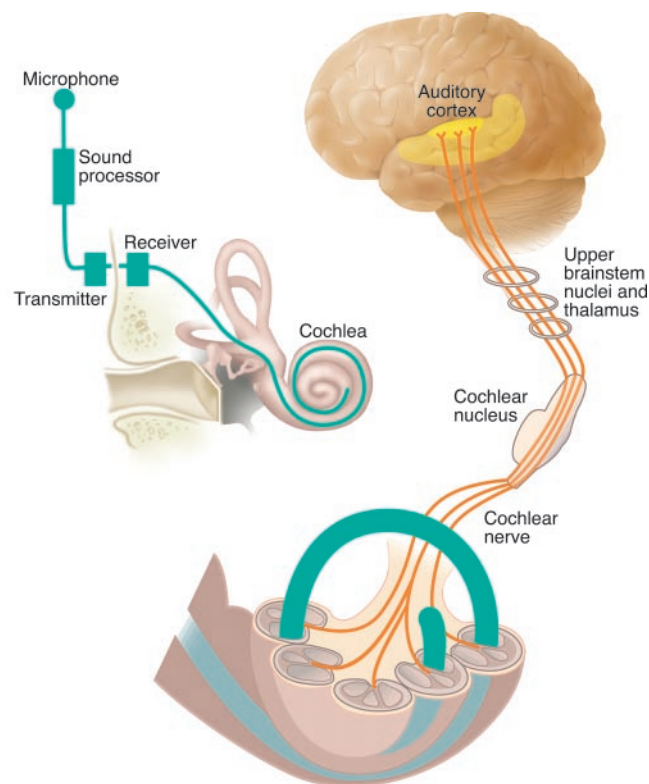
Early CIs were designed primarily to replace the lost function of the cochlea, with little regard to the way the brain processes and adapts to auditory information. Thirty years of research with CI patients have revealed new insights into the contributions of both the cochlea and the brain in auditory perception. These insights will prove to be invaluable for the next generation of brainstem auditory prostheses (and perhaps other neural prostheses as well). In CI devices, multiple stimulating electrodes embedded in a silicone matrix are inserted into the cochlea of the inner ear, so that the electrodes are situated at different locations along the cochlea's basilar membrane. The mechanics of the cochlea are such that the basilar membrane is tonotopically organized, that is, high-frequency sounds activate hair cells at the base of the basilar membrane, whereas low-frequency sounds activate hair cells near the apex of the basilar membrane. The sound, received by an external microphone, is first analyzed by a microprocessor, and an electrical signal representing the information from each frequency region is transmitted to the appropriate electrode at each tonotopic location (Fig. 1). Thus, CIs can access most of the frequency range of the cochlea, with the exception of the lowest frequencies represented by hair cells in the thinnest, narrowest winding part of the cochlear apex, which are inaccessible to most CI electrodes (5). Curious-

ly, this frequency range turns out to be largely unnecessary for speech transmission, perhaps because of a peculiar psychophysical phenomenon called "residue pitch." This effect was already known to Helmholtz in the 19th century as the phenomenon of the "missing fundamental" (6). As long as sounds contain enough overtones or harmonics, higher auditory processing centers in the brain, such as the auditory cortex, are able to "reconstruct" the missing fundamental frequency. The advantage for CIs (and modern telephones for that matter) is that frequencies below ~1000 Hz need not be transmitted for a clear understanding of speech, which helps to save valuable bandwidth. Thus, despite the relatively crude CI signal (in comparison to the original speech signal), delivered by a discrete and limited number of stimulating electrodes, most implant listeners are capable of excellent language understanding. Although much of the information coming from the cochlea is important for sound quality, music appreciation, or higher-order cues for the identification of sound objects, only a coarse representation of the auditory information from the cochlea is required for speech understanding (7). Processing by the auditory cortex fills in much of the missing information, just as the visual cortex fills in the blanks left by our blind spot or by illusory contours.

Obviously, a difference exists between

patients who become deaf before or after acquiring speech (pre- and postlingual deafness, respectively). Whereas the postlingually deaf "reconnect" almost immediately after receiving their CI, success in prelingually deaf individuals depends very much on the age of implantation. As with corrections of early visual defects, such as cataract or strabismus, the maxim is "the earlier the better" (2, 8). Thus, another fundamental and encouraging lesson learned from CI research is about the plasticity of neural representations of auditory information in the brains of young children—that is, in response to sound, the stimulated auditory cortex can recruit neurons from adjacent regions of the brain and can form new neuronal connections. Studies in congenitally deaf cats confirm the malleability of the auditory cortex, which is moulded by auditory experience from an early age (9). If environmental sounds transmitted via a microphone and CI are used to stimulate the central auditory pathways of young deaf cats, the animals soon begin to respond with appropriate behaviors to these sounds, and their auditory cortex begins to develop normal activation patterns. Much less plasticity is observed in congenitally deaf animals that are exposed to sound at an older age (9). These results are very much in tune with the visual-deprivation literature (10) and indicate the existence of a sensitive period during early

Fig. 1. The cochlear implant (CI). The auditory system is composed of the outer ear, the middle ear comprising the tympanic membrane and auditory ossicles, and the inner ear composed of the snail-like cochlea containing sensory hair cells bathed in fluid. These sensory hair cells activate the fibers of the cochlear (auditory) nerve, which emanate from the spiral ganglion cells and project to the cochlear nucleus of the auditory brainstem. The neural pathway then leads to the higher auditory processing centers of the brain: the inferior colliculus, medial geniculate nucleus, and primary auditory cortex. A CI consists of an external microphone, which collects sound waves, and a speech processor, which converts the sound waves into electrical impulses that are then transmitted to a receiver implanted under the skin. The receiver sends the electrical impulses to a microelectrode array implanted within the cochlea. The electrodes directly stimulate the correct populations of auditory nerve fibers so that electrical signals are propagated to the appropriate (tonotopic) regions of the cochlear nucleus of the brainstem and then on to higher auditory processing centers. [Illustration: Nathalie Cary/Katharine Sutliff]



postnatal development of the central auditory system, especially the auditory cortex (11, 12). Other examples supporting the existence of a sensitive period include early musical training in young children, which seems to lead to a higher incidence of absolute pitch and an enhanced sensitivity of the auditory cortex to complex harmonic sounds (13). The application of CIs is also creating renewed interest in and a new tool for the study of cortical plasticity in the adult auditory system. Some studies have shown remarkable perceptual plasticity in adapting to auditory patterns shifted in frequency (as they might be by a CI) (14), a result that is reminiscent of the perceptual learning in vision encountered when using inverting and displacing goggles (15). Other studies have not shown such plasticity and again suggest that auditory speech-pattern recognition may not be as malleable in adults (16). To effectively design and program auditory prostheses, it is important to understand the critical elements of auditory pattern recognition and the extent to which central plasticity can correct or compensate for distortions and omissions of incoming sound information.

CIs are not an option for those individuals whose deafness is caused by lesions beyond the cochlea. This includes a patient group with neurofibromatosis type 2 (NF2), a genetic disease that occurs in about 1 in 40,000 births (17). NF2 produces Schwann cell tumors along afferent nerve tracts as they enter the brainstem and spinal cord. One of the defining symptoms of NF2 is the growth of bilateral tumors along the eighth cranial nerve (composed of the auditory and vestibular nerves). Removal of the tumors almost always necessitates a transection of the auditory nerve and thus results in total deafness. If the tumors are not removed, they produce compression of the brainstem that is ultimately fatal. Faced with the tragic choice between total deafness and premature death, most patients, usually young people in the prime of life, opt for surgery, knowing full well

that they will wake up without hearing. Their only hope is that an auditory prosthesis such as an ABI that stimulates the brainstem directly may provide at least some limited hearing capability.

Existing ABI technology (implanted in ~200 patients so far) stimulates the surface of the ventral cochlear nucleus in the auditory brainstem, the next stage of auditory processing after the cochlea (18). The strategy is similar to that used in cochlear implants: An external speech processor and receiver transmit sound waves in the form of electrical impulses to an array of platinum electrodes that are implanted on the surface of the brainstem's ventral cochlear nucleus (Fig. 2). The microelectrode array is inserted through an opening in the mastoid bone behind the ear and is advanced into the lateral recess of the fourth ventricle of the brain, which is adjacent to the ventral cochlear nucleus. The ventral cochlear nucleus is part of the mainstream (lateral lemniscal) auditory system that transmits sound frequency information to higher auditory centers (inferior colliculus, medial geniculate nucleus, and auditory cortex) and is tonotopically organized (19–21). Unfortunately, its tonotopic map is oriented at a shallow angle to the surface. The effect of electrodes simply placed along the surface of the ventral cochlear nucleus is therefore tantamount to stimulation with a single electrode. The multiple microelectrode array often does not evoke different pitch sensations in ABI patients, whereas such pitch differences are routine in CI patients. It is therefore not surprising that the range of frequency information and the frequency resolution of these surface-electrode ABIs are not satisfactory and usually do not lead to an understanding of speech even after months and years of practice (22–24). Another factor contributing to the lack of tonotopic resolution in surface-electrode ABIs may be the high current needed for stimulation: Current fields spread broadly from each electrode and may not

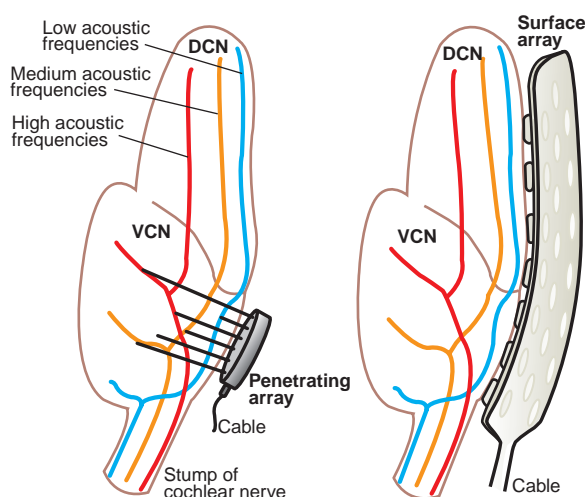
stimulate distinct neural populations.

Improvements in ABI performance require that the microelectrode array penetrates deep into the ventral cochlear nucleus. McCreery *et al.* (4) have successfully implanted such penetrating electrode arrays in cats and have demonstrated the ability of the electrode arrays to evoke tonotopically localized neural activation in the next auditory relay station of the brainstem, the inferior colliculus. The hope is that the improved tonotopic selectivity provided by penetrating microelectrodes will result in improved speech understanding in human patients. After 12 years of basic research, the Food and Drug Administration in the United States has approved the first clinical trial of the penetrating ABI in NF2 patients, and the first candidate is expected to undergo surgery in 2002.

Another reason for the limited success of the current ABIs may be that direct stimulation of the cochlear nucleus bypasses important intrinsic neuronal processing—that is, the cochlear nucleus may already contain specialized neural circuitry that extracts information on sound modulation and periodicity, and information on sound onset and offset. If penetrating electrodes do not result in a significant improvement in speech recognition, it could imply that such specialized processing in the cochlear nucleus is critical for speech understanding and cannot be recreated by prosthetic electrical stimulation. Such a failure would not bode well for a future auditory prosthesis that directly stimulates the inferior colliculus or auditory cortex. Both structures, particularly the inferior colliculus, would be more surgically accessible than the cochlear nucleus, which is located deep in the brainstem. Regarding direct stimulation of the auditory cortex, attempts to directly stimulate the visual cortex have been disappointing, with patients seeing only phosphenes (spots of light) or other disconnected and meaningless sensations (25). However, with the gains made by research on both the visual and auditory cortex, it may be possible to design new electrode arrays that stimulate the auditory cortex appropriately (26, 27).

Neuroimaging techniques, such as functional magnetic resonance imaging, will be valuable in the presurgical planning of stereotactically placed ABIs that must penetrate deep into small brainstem structures (28, 29), particularly if neuroimaging can illuminate tonotopic organization in individual patients (30). Stereotactic neurosurgical interventions could eventually help to widen the use of auditory prostheses for binaurally deaf patients with other etiologies, such as an absent or malformed inner ear or a basal skull fracture. Long-term stereotactic electrode implants are technically feasible and can be highly beneficial for patients with chronic debilitating diseases. For example, deep brain

Fig. 2. Auditory brainstem implant (ABI). Both panels show a section through the brainstem that reveals the dorsal and ventral regions of the cochlear nucleus (DCN, VCN). Depicted are two types of ABI in which the microelectrode array is either placed on the surface of the cochlear nucleus (right panel), or penetrates the VCN (left panel). The tonotopic organization of the VCN is such that iso-frequency regions run at a shallow angle almost parallel to the VCN surface. This explains why penetrating ABIs provide more selective tonotopic stimulation than surface ABIs. [Illustration: Nathalie Cary]



stimulation of the subthalamic nucleus of Parkinson's patients with a stereotactically placed electrode results in alleviation of many of the motor symptoms of this disease (31).

Clearly, CIs and ABIs not only are of benefit to profoundly deaf individuals but also continue to provide insight into information processing in the auditory nervous system. And certainly, each new understanding achieved in basic scientific research will result in improvements to the technology of auditory prostheses, and increased benefits for patients.

References and Notes

1. G. E. Loeb, *Annu. Rev. Neurosci.* **13**, 357 (1990).
2. J. P. Rauschecker, *Science* **285**, 1686 (1999).
3. B. J. Edgerton, W. F. House, W. Hitzelberger, *Ann. Otol. Rhinol. Otolaryngol.* **91** (suppl.), 117 (1984).
4. D. B. McCreery, R. V. Shannon, J. K. Moore, M. Chatterjee, *IEEE Trans. Rehabil. Eng.* **6**, 391 (1998).
5. The cell somata of nerve fibers coming from the apical turn of the human cochlea are not located in the center of the apical coil, but more toward the middle turn. If one assumes that CI electrodes stimulate fibers en passant, they may stimulate low frequencies too, even though the electrodes do not extend all the way into the apical turn.
6. H. L. F. Helmholtz, *Die Lehre von den Tonempfindungen als physiologische Grundlage für die Theorie der Musik* (Vieweg, Braunschweig, Germany, 1863).
7. R. V. Shannon, F.-G. Zeng, J. Wygonski, V. Kamath, M. Ekelid, *Science* **270**, 303 (1995).
8. M. A. Svirsky, A. M. Robbins, K. I. Kirk, D. B. Pisoni, R. T. Miyamoto, *Psychol. Sci.* **11**, 153 (2000).
9. R. Klinke, A. Kral, S. Heid, J. Tillein, R. Hartmann, *Science* **285**, 1729 (1999).
10. T. N. Wiesel, *Nature* **299**, 583 (1982).
11. J. P. Rauschecker, *Trends Neurosci.* **18**, 36 (1999).
12. J. K. Moore, Guan, *J. Assoc. Res. Otolaryngol.* **2**, 297 (2001).
13. C. Pantev et al., *Nature* **392**, 811 (1998).
14. S. Rosen, A. Faulkner, L. Wilkinson, *J. Acoust. Soc. Am.* **106**, 3629 (1999).
15. I. Kohler, *The Formation and Transformation of the Perceptual World [Über Aufbau und Wandlungen der Wahrnehmungswelt]* (International Univ. Press, Vienna, 1951), R. M. Rohrer, transl. (International Univ. Press, Vienna, 1964).
16. Q.-J. Fu, R. V. Shannon, J. Galvin, in preparation.
17. D. G. R. Evans et al., *J. Med. Genet.* **29**, 841 (1992).
18. D. E. Brackmann et al., *Otolaryngol. Head Neck Surg.* **108**, 624 (1993).
19. J. K. Moore, K. K. Osen, *Am. J. Anat.* **154**, 393 (1979).
20. In contrast to the VCN, the dorsal cochlear nucleus (DCN) contains neurons with complex response properties already at this early phase of processing and may be involved in early stages of spatial hearing (21).
21. E. D. Young et al., *Philos. Trans. R. Soc. London Ser. B* **336**, 407 (1992).
22. However, speech perception in combination with lip-reading is markedly improved (23, 24).
23. D. Matthies et al., *J. Laryngol. Otol. Suppl.* **27**, 32 (2000).
24. S. R. Otto et al., *J. Neurosurg.*, in press.
25. G. S. Brindley, W. S. Lewin, *J. Physiol.* **196**, 479 (1968).
26. R. A. Normann, E. M. Maynard, P. J. Rousche, D. J. Warren, *Vision Res.* **39**, 2577 (1999).
27. Q. Bui, K. D. Wise, D. J. Anderson, *IEEE Trans. Biomed. Eng.* **47**, 281 (2000).
28. A. R. Guimaraes et al., *Hum. Brain Map.* **6**, 33 (1998).
29. T. D. Griffiths, S. Uppenkamp, I. Johnsrude, O. Josephs, R. D. Patterson, *Nature Neurosci.* **4**, 633 (2001).
30. C. M. Wessinger et al., *J. Cognit. Neurosci.* **13**, 1 (2001).
31. M. R. DeLong, T. Wichmann, *Ann. Neurol.* **49**, 142 (2001).

VIEWPOINT

Repairing the Injured Spinal Cord

Martin E. Schwab

Certain cell, molecular, and bioengineering strategies for repairing the injured spinal cord are showing encouraging results (either alone or in combination) in animal models, with limited recovery of mobility being reported in some cases.

Our spinal cord is a finger-thick strand of nervous tissue that is tightly enclosed in the bony vertebrae of the spinal column. The spinal cord receives sensory information from the skin, the muscles, the joints, and other tissues of the body. It transmits this information in the form of electrical impulses to the brain, along millions of nerve fibers that are grouped together in bundles. The motor commands that are subsequently generated in the brain are sent to the spinal cord along fast-conducting nerve fibers, which terminate in local spinal motor circuits. From here, the electrical impulses that will direct coordinated muscle contraction reach the muscles via the peripheral nerves. A sharp blow to the spinal column can cause dislocation of individual vertebrae and severe damage to the spinal cord, including its complete severance. Clinically, the result of an incomplete or complete spinal cord lesion is either paraplegia (paralysis of the lower body) or quadriplegia (paralysis of the body from the neck down), depending on whether

the injury was sustained in the thoracic/lumbar region or neck region of the spinal column, respectively.

Destruction of the spinal cord can be compared to a bomb exploding in a computer center, and repairing the spinal cord is as complicated as trying to rebuild all of the computer connections. In the last few years, there has been encouraging progress in animal models, with sufficient regeneration of the damaged spinal cord to enable some recovery of motor ability. When the spinal cord is injured, the first phase of injury involves mechanical tissue destruction. It is followed by a second phase of tissue loss, which is principally caused by a severe local disturbance of the blood supply (1, 2). There have been attempts to minimize this secondary damage with neuroprotective agents, but, so far, only high-dose methylprednisolone (a synthetic corticosteroid) given within the first hours after injury is in use clinically (2, 3). Within several weeks of the injury, macrophages migrating from the bloodstream have cleared the tissue debris at the lesion site, resulting in fluid-filled cysts surrounded by scar tissue (Fig. 1). Whether this inflammatory reaction leads to additional damage of spinal cord tissue that is still intact remains a matter of debate.

Remarkably, images of the lesioned spinal

cord in paraplegic or quadriplegic patients show that complete anatomical separation of the spinal cord is very rare. Instead, bridges of nerve tissue (tracts) connecting regions above and below the lesion often persist, mostly at the peripheral edges of the spinal cord (4). This type of anatomically incomplete spinal cord lesion has been recreated in rats and other animals, either by microsurgical transection of defined regions of the spinal cord or by crushing the cord with metal rods of different weights. These animal models are valuable tools with which to test various spinal cord repair strategies.

There are four principal strategies for repairing spinal cord lesions: (i) promoting the regrowth of interrupted nerve fiber tracts, using nerve growth stimulatory factors or molecules that suppress inhibitors of neuronal extensions (neurites); (ii) bridging spinal cord lesions with scaffolds that are impregnated with nerve growth factors, which promote axon growth and reduce the barrier caused by scar tissue; (iii) repairing damaged myelin (the insulating sheath that surrounds axons) and restoring nerve fiber impulse conductivity in the lesion area; and (iv) enhancing central nervous system (CNS) plasticity by promoting compensatory growth of spared, intact nerve fibers above and below the lesion.

Regeneration of Nerve Fiber Tracts

Crushed or transected nerve fibers in the CNS of the adult often react with a spontaneous,

Brain Research Institute, University of Zürich, and Department of Biology, Swiss Federal Institute of Technology Zürich, Winterthurerstrasse 190, 8057 Zürich, Switzerland.